

Case Study of an Obese Patient with a Large Sacral Pressure Ulcer

A Andriessen¹, R van Dam², A van den Wijngaard³

1. PhD, UMC St Radboud Nijmegen & Andriessen Consultants, Malden, The Netherlands. 2. RN, Pressure Ulcer Specialist, Verpleeghuis Boerhaave Stichting Sint Jacob 2035 RJ Haarlem, The Netherlands.
3. RN, CNS, Wound Care and Compression Specialist, Lohmann & Rauscher, Almere, The Netherlands

Aim:

Although education on pressure ulcer prevention has improved, extensive pressure ulcers do occur, especially in complex situations such as obesity.
The aim was to provide tailor made solutions to achieve an optimal outcome.

Methods:

- ✓ Case ascertainment was used addressing the complex psychological and physical issues that arise in the 64-years old obese male.
- ✓ His weight was 160 kg and his height was 1.70 meter.
- ✓ In a short period of time he had lost 50 kg for no obvious reason.
- ✓ He lived alone, was inactive, incontinent of both urine and faeces and spent most of his time sitting in a chair.
- ✓ He had developed a class 3 (EUPAP classification) sacral pressure ulcer that was initially unsuccessfully treated at home.

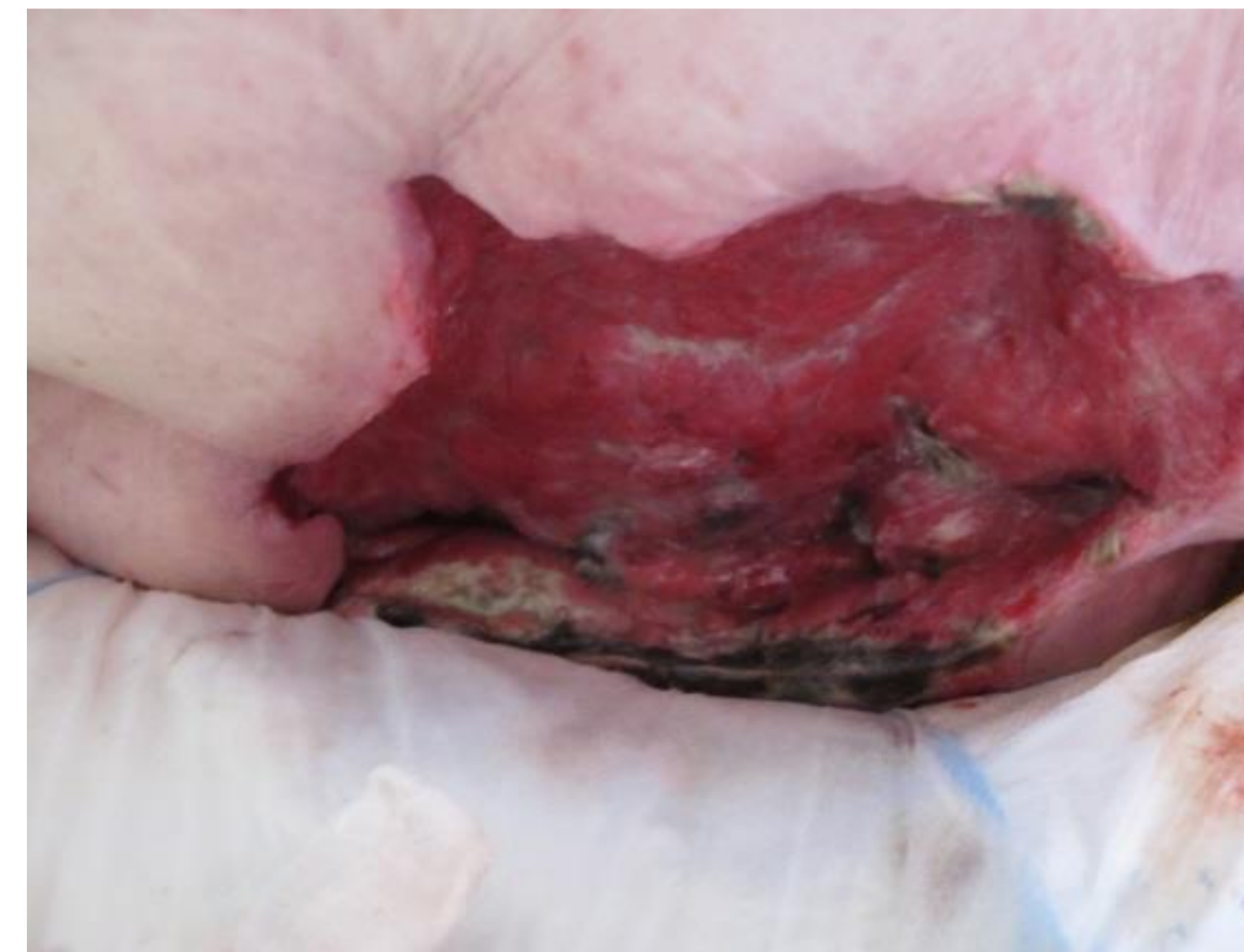
Results :

Upon admission to the hospital, surgical debridement was performed leaving an ulcer of 21 x 15 x 6 cm. During hospital stay 2 grade 4 heel ulcers developed. After 1 month he was transferred to a nursing home, where he received an air mattress and foam to off-load his heels. He received education on his condition and a dietician was consulted.

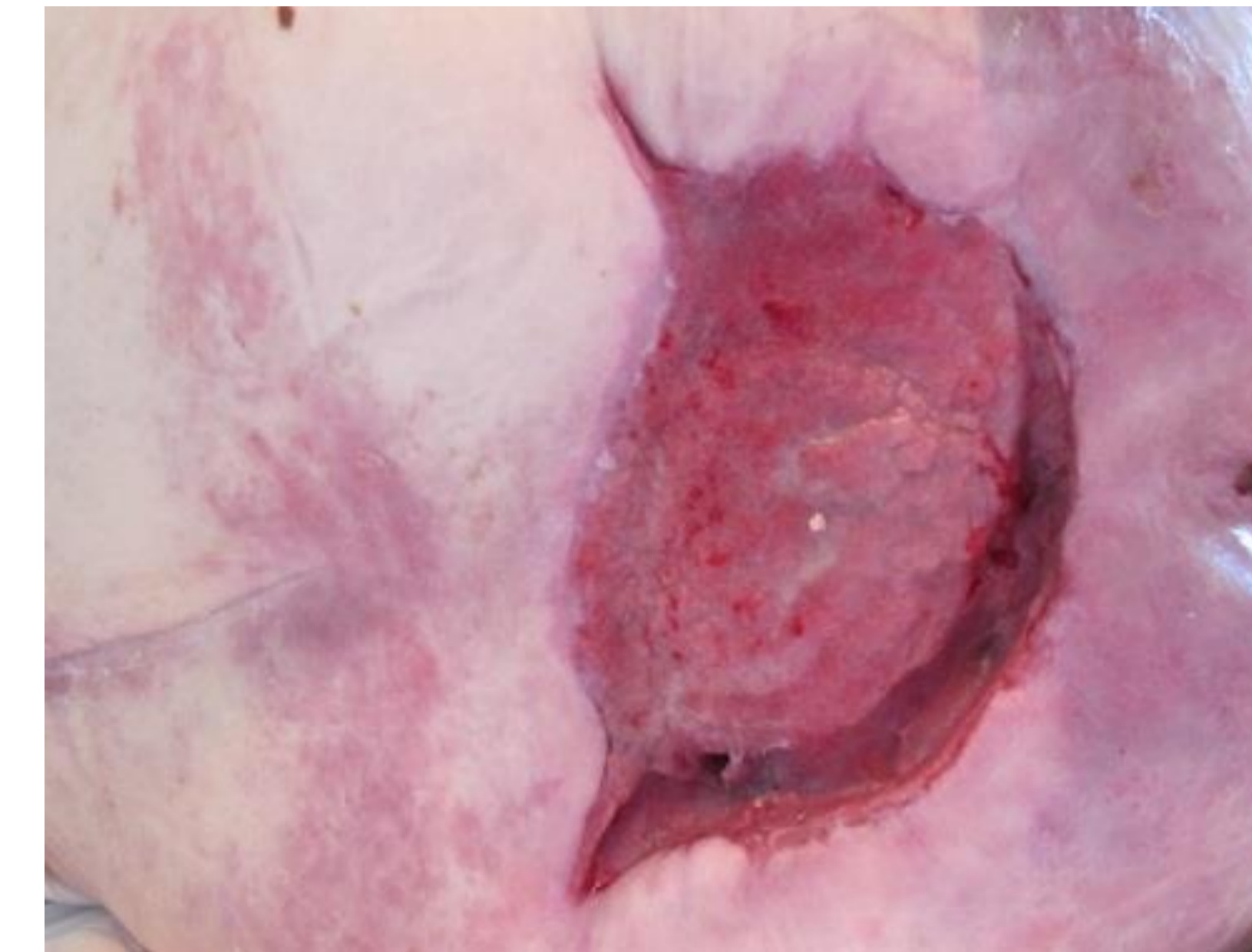
The heel ulcers measured 8 x 8 cm and had black necrosis, which was debrided. Both legs were swollen with oedema, which was addressed with compression bandages. Sacral ulcer closure was achieved within 13.5 weeks and the heel ulcers had markedly improved.

Conclusion :

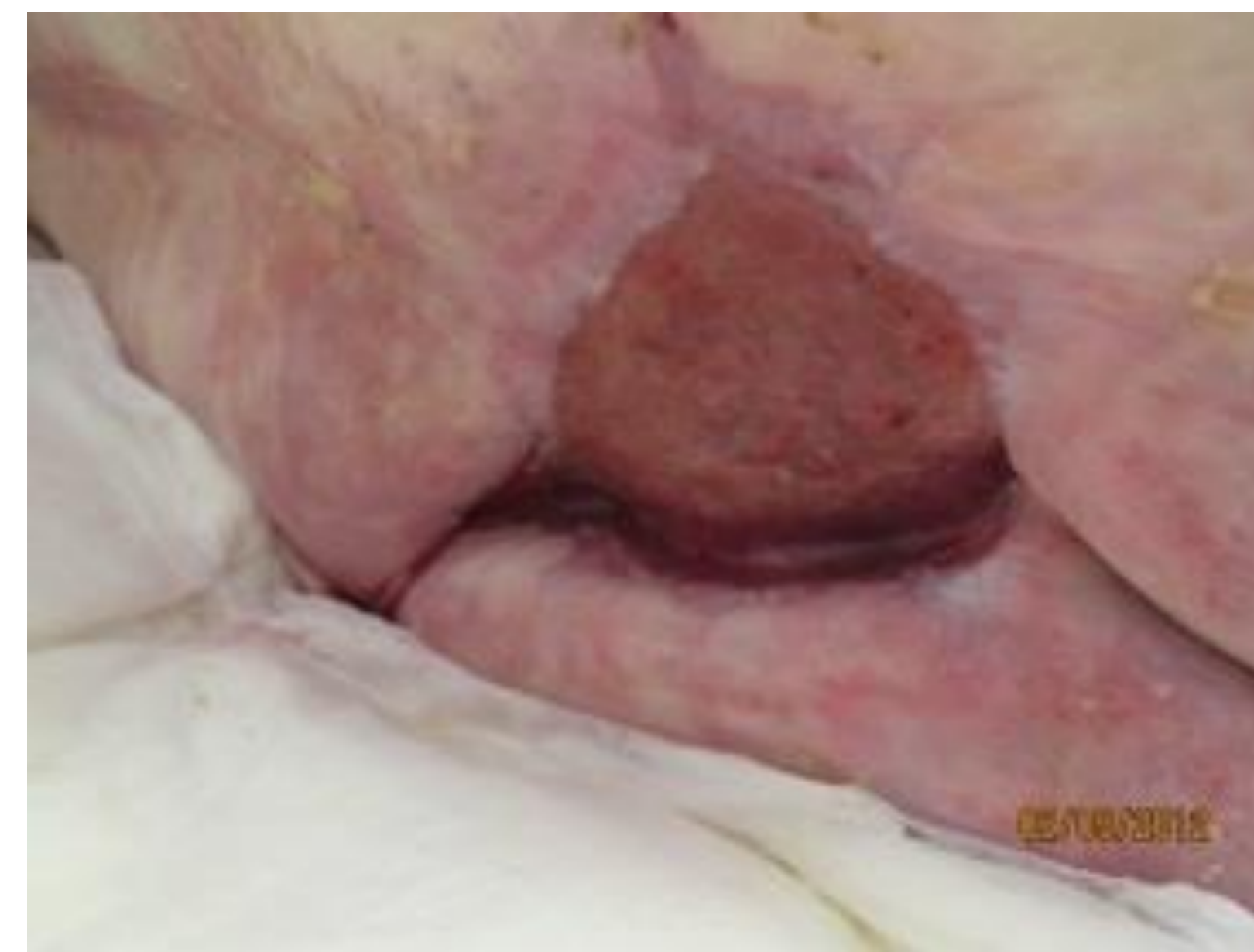Addressing specific patient issues combined with optimal wound care was shown to be successful.



Visit 1 @ 15-02-2012
The granulating sacral ulcer was covered with a collagen* dressing, a silver alginate** and an absorbent pad***, fixed with a film**** dressing.



Visit 2 @ 28-03-2012
Ulcer size: 16 x 11 x 2 cm
Had reduced with 5 x 4 x 4 cm after 42 days. The same dressing regime is continued.



Visit 3 @ 02-05-2012
Ulcer size: 8.5 x 8 x 1.3 cm. Dressing changes using the same regimen now takes place 3 x / week.

