Successful treatment of a Malum perforans with total contact cast and moist wound management – a case study

Denius P.[1], Sommer N. [2], Koggel A.[1]

[1]*Lohmann & Rauscher GmbH & Co KG, D-56579 Rengsdorf*
[2]*Praxis für Allgemeinmedizin, 35713 Eschenburg*

Introduction

Diabetic foot ulcerations are worldwide a most common precursor of lower-limb amputations. According to estimates for Germany almost 29000 diabetes patients suffered an amputation in 2001. This corresponds to nearly 70% of all non-traumatic amputations in 2001 (1). An effective off-loading of the diabetic lesions has been recognised as an essential part of the ulcer treatment. Whilst Total Contact Casts (TCCs) are considered the „gold standard“ of the pressure-relieving methods in the United States (2), this off-loading principle is only poorly applied in Germany so far. Therefore this case study was performed to assess the use of off-loading by a fibreglass-TCC in combination with moist wound treatment.

Method

The 57-year-old male patient, 200 cm, 180 kg, forefoot amputation on the left foot following a superinfected malum perforans, suffers from diabetes since 1975. The treatment of a newly developed malum perforans (see figure 1 a), which was present for 6 months, included wound debridement/removal of callus (see figure 1 b), moist wound management with hydrogel (Suprasorb® G), collagene (Suprasorb® C) and polyurethane membrane (Suprasorb® M) (see figure 1 c) and a removable fibreglass-Total Contact Cast on the lower leg. The Total Contact Cast consisted of skin protection (tg® Tubular Bandage), padding (Cellona® Synthetic Undercast Padding, Cellona® Adhesive Padding), fibreglass cast (Cellacast® Xtra) and a walking heel (Cellona® Walking Heel). For the regular wound inspection, the TCC was opened and fixed with hook and loop fasteners (see figure 2 a-d). Wound dressings were changed every 2 to 3 days without the patient being allowed to remove the TCC meanwhile.

(a) Malum perforans approx. 6 months old

(b) Removal of callus

(c) Modern wound-management (here: Suprasorb®C)

Figure 1

(a) Application of the TCC

(b) Opening of the TCC

(c) Fixation with hook and loop fasteners

(d) TCC in use

Figure 2

Results

At the beginning of the treatment the wound size was approximately 30 cm² (see figure 3 a). After four weeks of treatment with the combination of TCC and moist wound dressings the wound size was reduced to approx. 10 cm² (see figure 3 b). Wound healing continued over the next weeks (see figure 3 c-d) and a complete healing of the malum perforans was achieved after twelve weeks of treatment. Due to a crack in the fibreglass material, the TCC had to be renewed once in week seven.

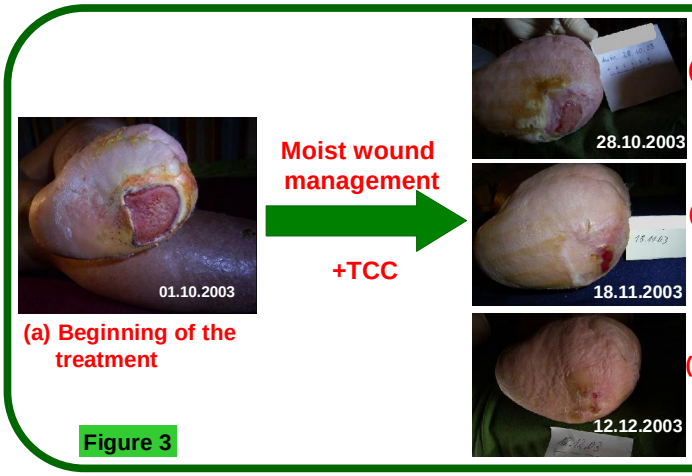

(a) Beginning of the treatment

(b) After 4 weeks

(c) After approx. 7 weeks

(d) After approx. 10 weeks

Figure 3

Conclusions

The fast healing process of the six months persisting malum perforans impressively underlines the efficacy of the combination of pressure-relief by a removable TCC and moist wound treatment. The fibreglass cast Cellacast® Xtra proofed to be stable for a seven week period, even with the patients over-average body weight of 180 kg. Due to the good experiences reported in this case study, this concept of treatment is worth to be implemented in the therapy of diabetic foot ulcers in Germany as well.

References:
1. G. Heller et al. Wie häufig sind Diabetes-bedingte Amputationen unterer Extremitäten in Deutschland? Eine Analyse auf Basis von Routinedaten. Dtsch med Wochenschr 2004; 129: 429-433.
2. American Diabetes Association. Consensus Development Conference on Diabetic Foot Wound Care. Diabetes Care 1999; 22:1354-1360

Joint meeting between ETRS, EWMA und DGfW, Stuttgart, 14-17 September 2005

Lohmann Rauscher