



When a Foam Dressing isn't enough: Exudate Management in a Surgically Debrided Pressure Injury

Sian Fumarola, Tissue Viability Specialist Nurse, North Staffordshire Hospital, Stoke on Trent, UK

Aim: To examine the role of exudate in acute and chronic wounds in assisting or impeding wound healing.

Method: The tissue viability nurse specialist is responsible for wound care throughout the acute hospital trust, working closely with general and plastic surgeons, theatre staff and ward staff and implementing a triage system to identify problem wounds and decide on treatment.

Increased levels of tissue damage from chronic wounds such as pressure ulcers and an associated exudate burden are increasing problems due to an ageing population, even with modern wound care (Moore 2003). Unlike acute wound fluid, exudate in these wounds is laden with harmful proteases which delay healing (WUWHS 2007).

When managing exudate the practitioner considered the rate of absorption, removal of unwanted by-products, care of the peri wound skin, comfort to the patient, and ease of use by nurses.

The study sets out to describe how these challenges are being overcome through the use of new, superabsorbent dressings and the skill and leadership of the tissue viability nurse.

Results: A new superabsorbent dressing Flivasorb, was used successfully on a previously hard to manage sacral pressure ulcer where dressing application and securing were particularly challenging. Superabsorbent dressings are used to manage large volumes of fluid and they have been shown to remove harmful proteases from wounds. (Wiegand 2008) The dressing conformed well to the sacral area and was covered with a semi-occlusive film dressing to seal it and to keep it in place. Exudate levels reduced and the surrounding skin improved; additionally the ward nurses were able to manage this wound with minimal supervision.

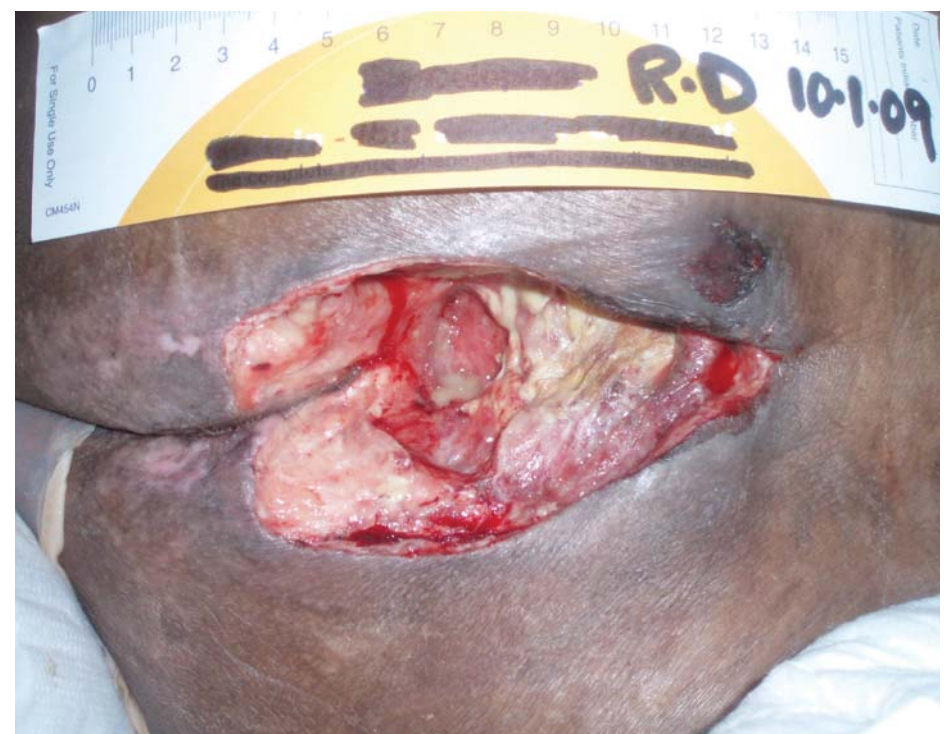
Conclusion: Wound care relies on the use of many treatment modalities, combined with effective communication between staff to achieve a positive outcome for the patient.

References:

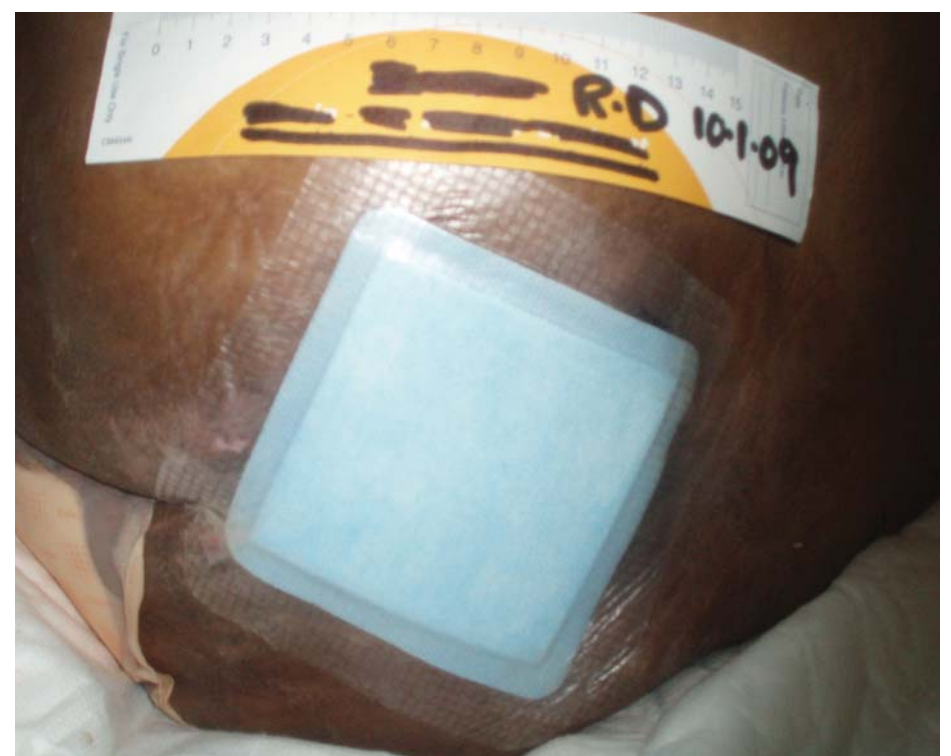Moore K (2003) Compromised wound healing: a scientific approach to treatment, British Journal of Community Nursing 8, (6) : 274-278

World Union of Wound Healing Societies (WUWHS) Principles of Best Practice; Wound exudates and the role of dressings. A consensus document. London; MEP Ltd 2007.

Wiegand C, Abel M, Ruth P, Hipler U.-C, (2008) Polyacrylate superabsorbers bind inflammatory proteases in vitro, Wounds UK Conference, Harrogate



Surgically debrided, heavily exuding sacral pressure ulcer



Flivasorb superabsorbent dressing in situ. Correct application ensured conformability, patient comfort and a good seal