

# EFFECTIVE REMOVAL OF OCCUPATIONAL TRAUMATIC SKIN TATTOO WITH A MONOFILAMENT FIBRE DEBRIDEMENT PAD\*

Lars Hofmann<sup>1</sup>, Claas Roes<sup>2</sup>, Cornelia Erfurt-Berge<sup>1</sup>

<sup>1</sup> University Hospital Erlangen, Department of Dermatology, Friedrich-Alexander University Erlangen-Nürnberg, Germany, <sup>2</sup> Lohmann & Rauscher GmbH & Co. KG, Rengsdorf, Germany



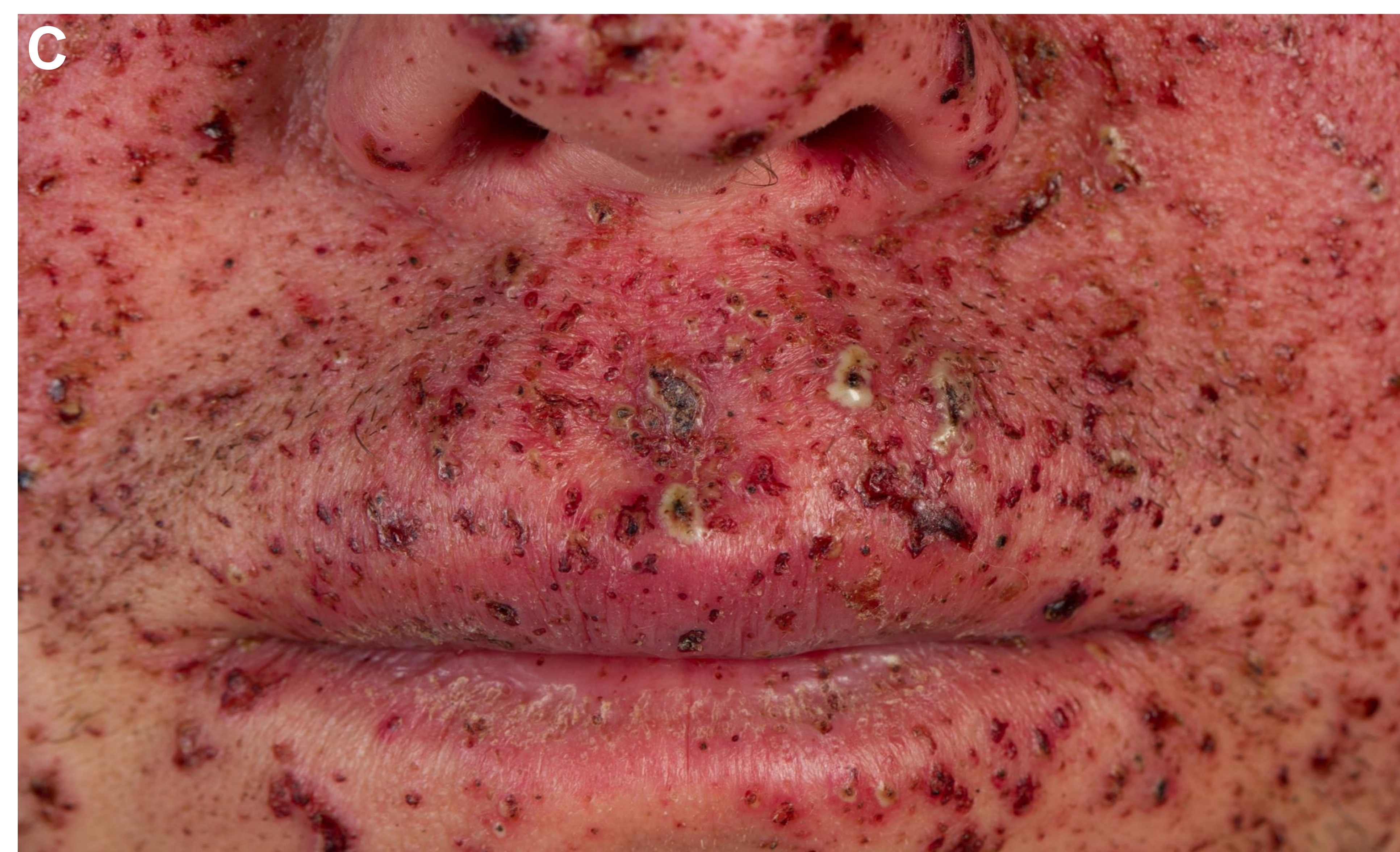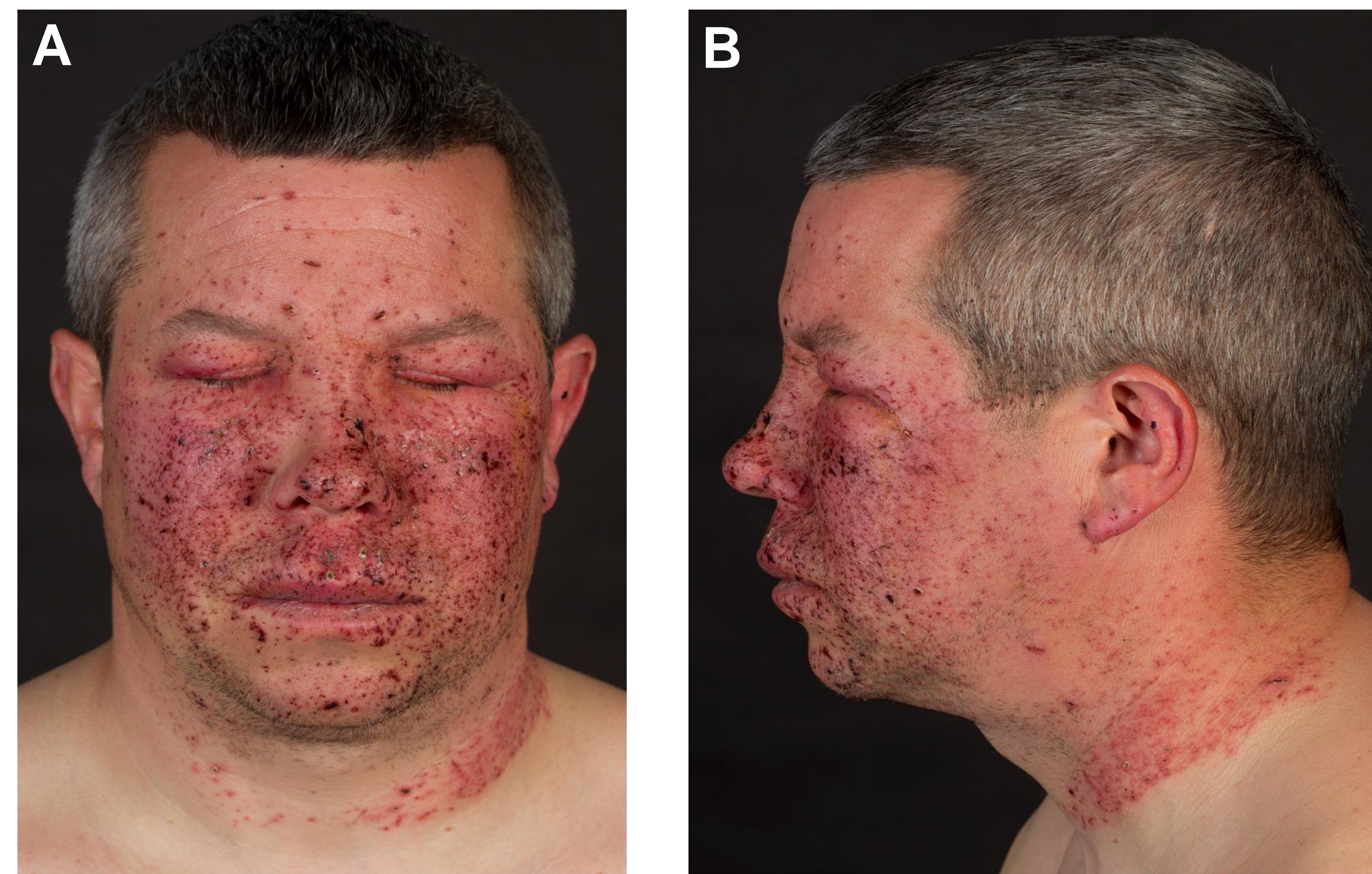# Effective removal of occupational traumatic skin tattoo with a monofilament fibre debridement pad\*

## INTRODUCTION:

Traumatic implantation of pigmented particles in the skin can derive from fireworks, gunpowder or road rush injuries and require removal as quickly as possible to prevent deeper penetration of the foreign bodies and persisting skin tattoo. We present the case of a young male patient with accidental contamination during his work as a channel digger.

## METHOD:

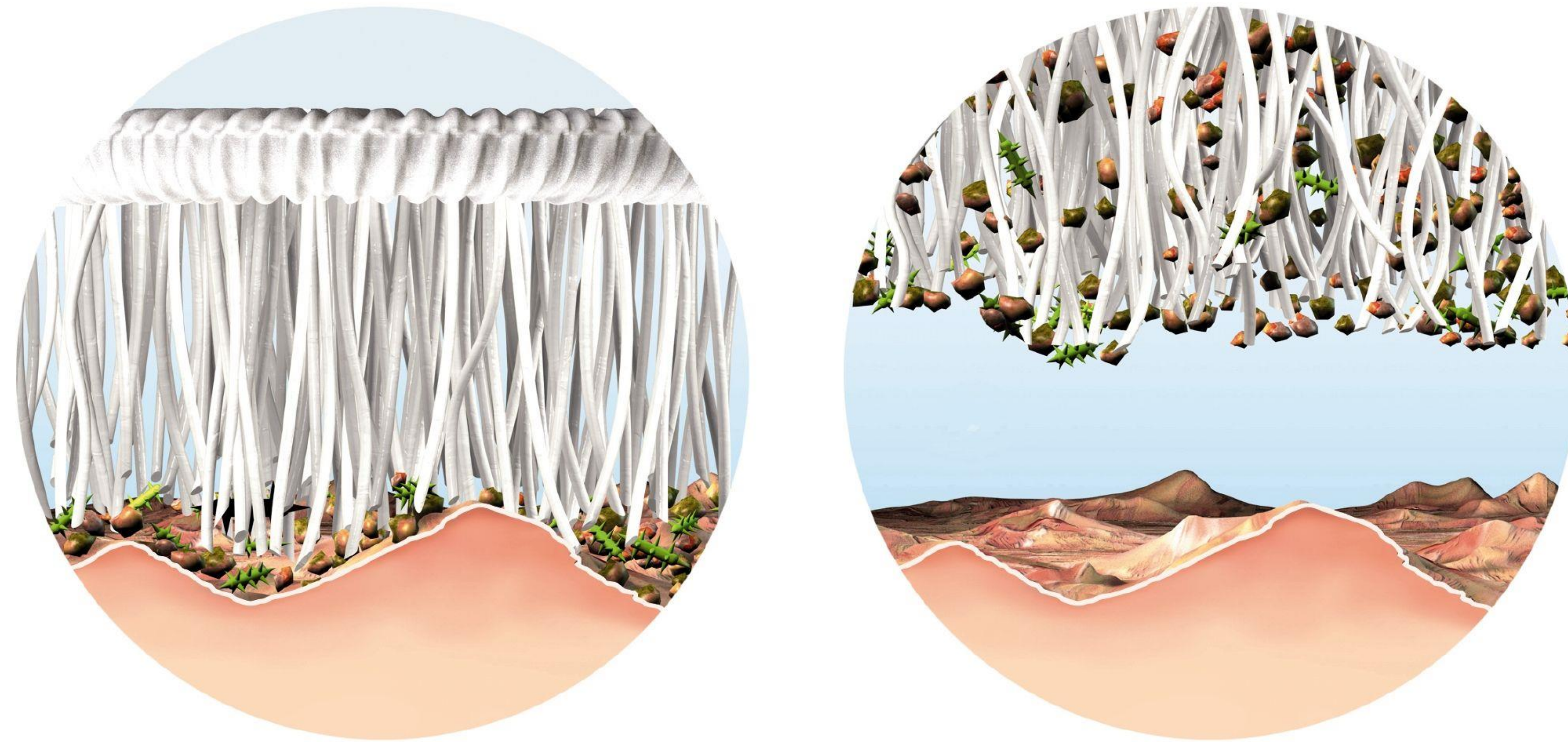
A 39-year-old male patient is employed as a channel digger. During his work impermeable cushions were inflated under pressure within the sewage-filled channel to dewater it for cleaning. One of the cushions burst when the patient was just 1-2 metres away. Water and mud exploded within the channel and covered the face and hands of the patient which were not protected by clothing. Dirt particles penetrated the skin and even the eyes and cornea (Panel A, B). The patient was hospitalized at the Department of Ophthalmology and after surgical removal of particles from the cornea topical and systemic antibiotic therapy was started. The day after the accident the patient was presented at the Department of Dermatology for the treatment of the dirt particles embedded in the facial skin. Next to multiple black spots, where foreign bodies had entered the skin, punctiform pustules and crusts covered the skin of the central face and partly the neck (Panel C). Several bacterial species could be found after examination of a skin swab. Cheeks and periorcular region showed remarkable oedema. Laboratory examination revealed a C-reactive protein of 49.3 mg/l (normal: <5 mg/l).



## PANEL A, B, C: BEFORE DEBRIDEMENT.

Dirt particles penetrated the skin and even the eyes and cornea (A, B). Punctiform pustules and crusts covered the skin of the central face and partly the neck (C).

# Effective removal of occupational traumatic skin tattoo with a monofilament fibre debridement pad\*

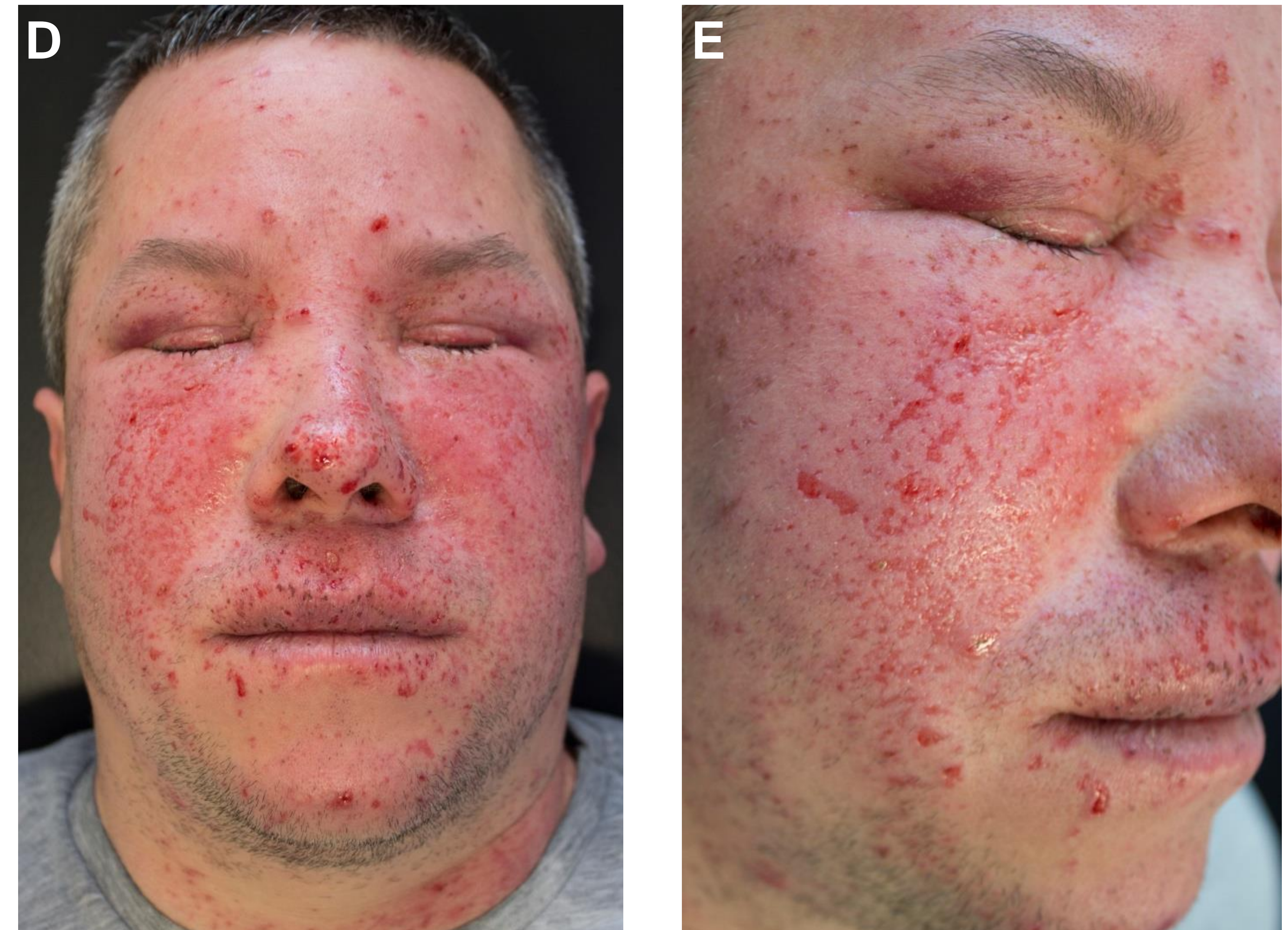

**FIGURE 1**

The angled tips actively loosen the debris and exudate from the wound and the fibre-composite absorbs and retains the pustules, dirt particles and crusts.

## RESULTS:

After an intensive rehydration of the skin with aliphatic ointments (0.4 mg/ml Polihexanid in Unguentum leniens) under semi-occlusive dressing over 4 hours, a mechanical debridement with a monofilament fibre debridement pad was performed. The immediate comparison with the use of moistened compresses showed a clear predominance of the monofilament pad in the efficiency of particle removal. Almost all particles could be eliminated leaving superficial skin lesions - pain-free (Panel D+E). Antiseptic ointment (Clioquinol 5 mg/g) was recommended for the further skin treatment. The systemic antibiotic therapy was also continued. A follow-up two days after the debridement showed a decrease of oedema and inflammation and a skin totally cleared from dirt particles (Panel F-H next page).



## PANEL D, E: IMMEDIATELY AFTER DEBRIDEMENT.

The pustules have been opened, dirt particles and crusts have been removed by the monofilament debridement pad. The skin has not been damaged any further.

- 4 hours antiseptic W/O ointment (0.4 mg/ml Polihexanid in Unguentum leniens) and semi-occlusive dressing
- Gently circling movements using the monofilament fibre debridement pad
- Almost pain-free without additional local anaesthesia

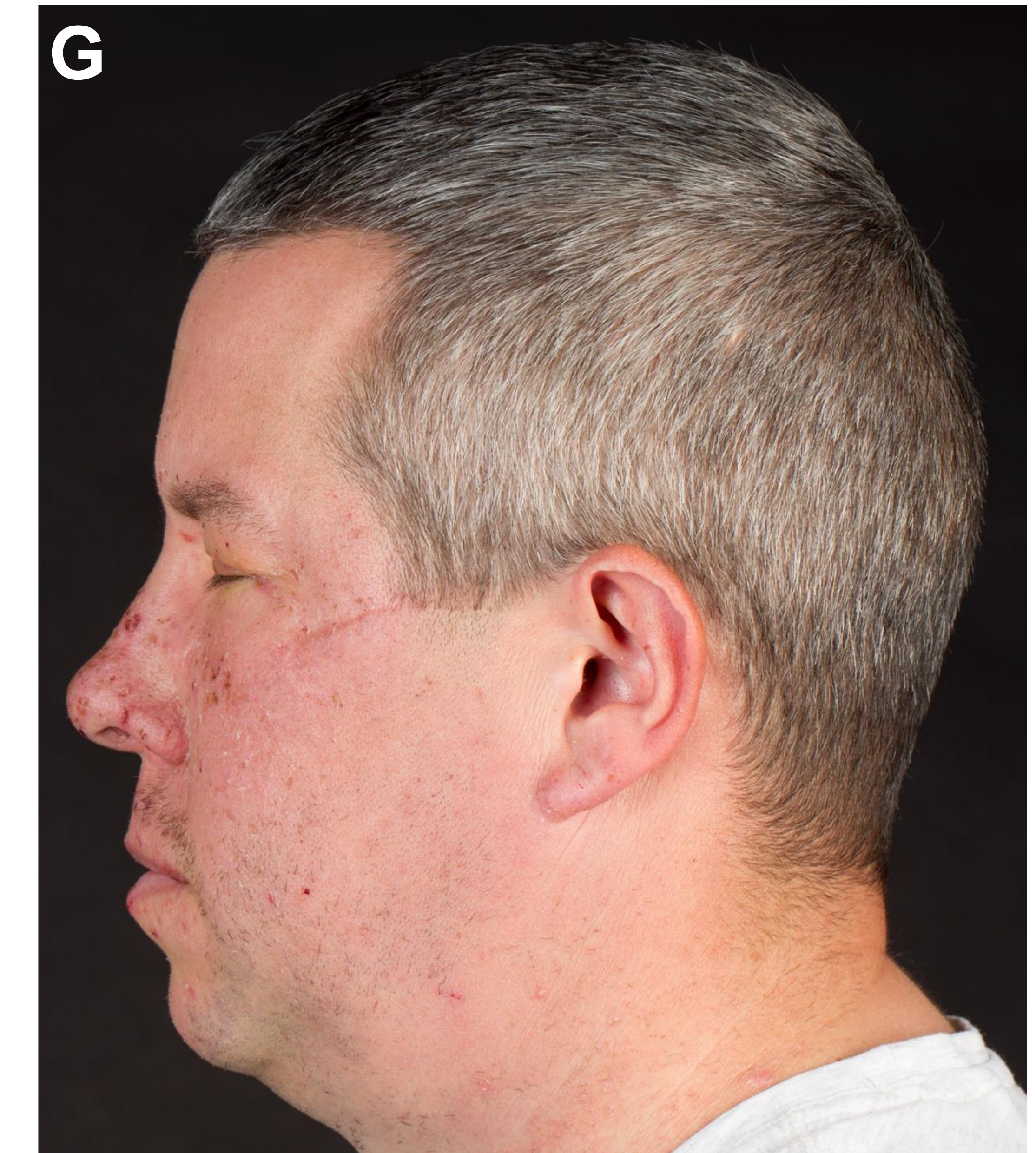
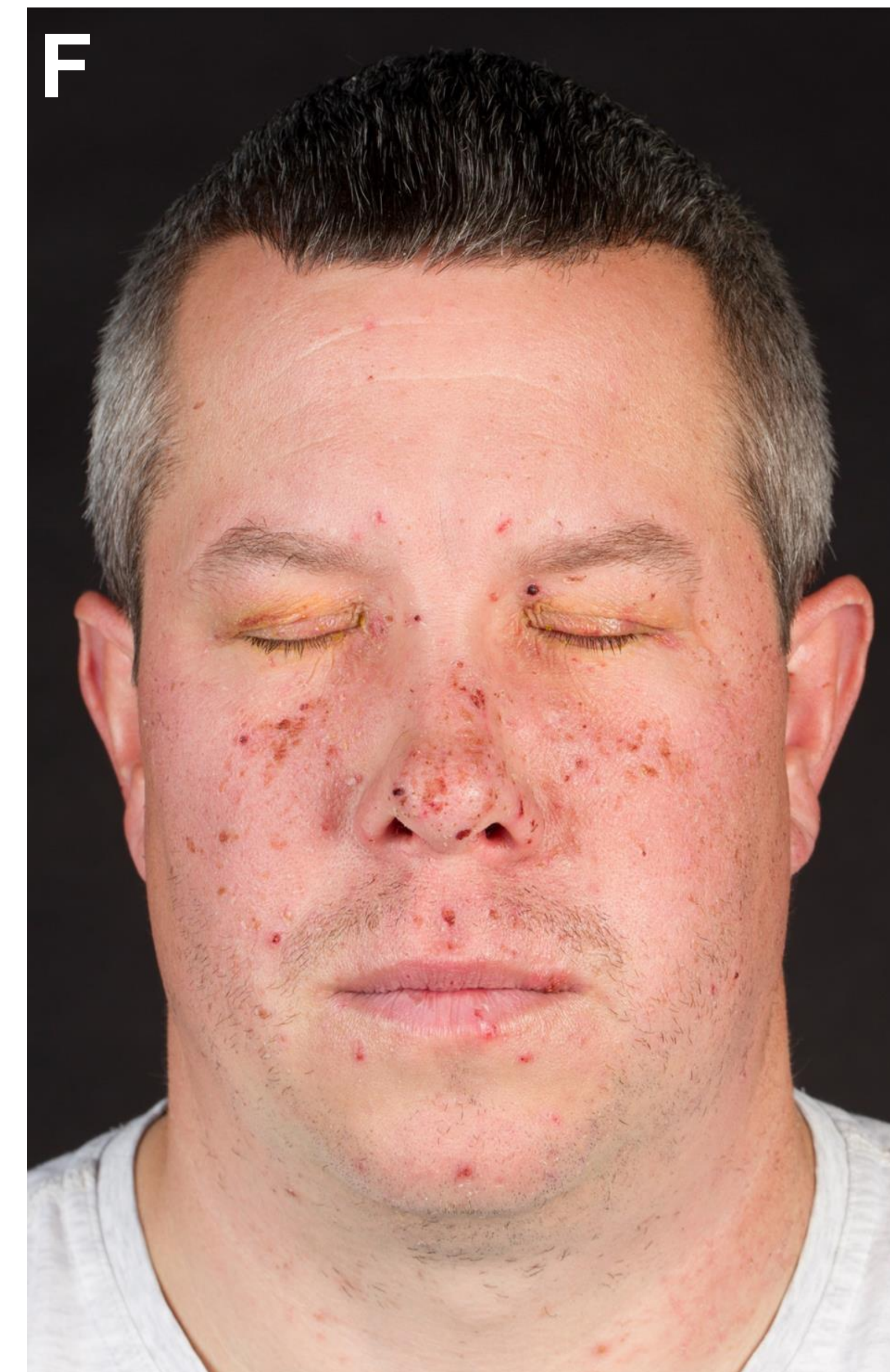# Effective removal of occupational traumatic skin tattoo with a monofilament fibre debridement pad\*

## DISCUSSION:

Removal of explosive residues embedded in the skin, especially in critical areas like the face, has to be performed as soon as possible to prevent deeper infiltration or scarring and to reveal best clinical outcome. Usual treatments with scalpel blade or dermabrasion are time-consuming and painful for the patients. By the use of a monofilament fibre debridement pad\* in an early stage of traumatic tattoo, a very satisfying cosmetic result could be achieved.

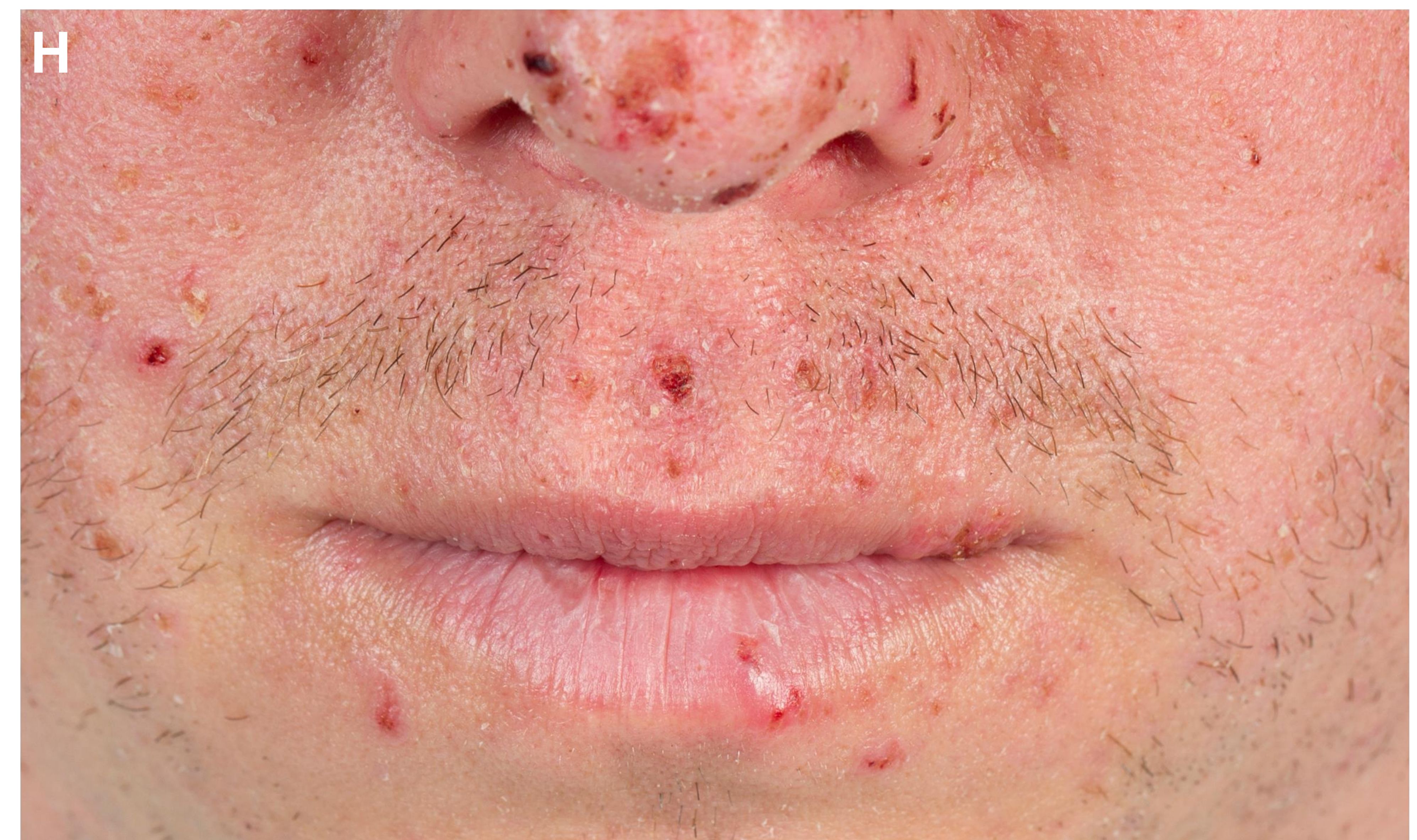## CONCLUSION:

The monofilament fibre debridement pad can be easily applied and represents a well tolerable, non-invasive debridement method to remove traumatic tattoos effectively at an early point of time.



## PANEL F, G, H: TWO DAYS AFTER DEBRIDEMENT.

The follow-up showed a decrease of oedema and inflammation two days after the debridement. Furthermore the skin is totally cleared from dirt particles.



## CONTACT

Department of Dermatology, University Hospital Erlangen,  
Ulmenweg 18, 91054 Erlangen, Germany  
Lars.Hofmann@uk-erlangen.de  
<http://www.hautklinik.uk-erlangen.de/>