

SUPRASORB® X – A NEW HYDROBALANCE WOUND DRESSING AND ITS USE IN CHRONIC WOUNDS

Krenmayer H¹, Sauer B², Schmitz M³

¹ Deutsches Institut für Wundheilung, D-78315 Radolfzell

² Sauer & Knorr, D-56566 Neuwied

³ Lohmann & Rauscher GmbH & Co KG, D-56587 Rengsdorf



Gesundheitsverbund HBH-Kliniken
Nah bei Ihnen



Deutsches Institut für Wundheilung

Introduction:

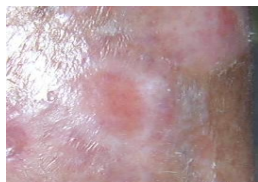
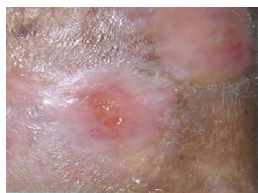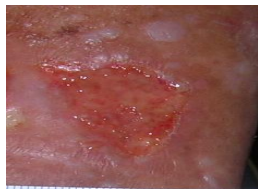The treatment of chronic wounds is a daily challenge for all nurses and physicians. Beside the basic-therapy of the disease, the selection of the adequate wound dressing plays an important role. Regarding to the growing number of materials and products on the market the situation is more and more complex for the prescriber and the user. One approach are products with a broad use in the different stages of exudation and wound healing. First practical experiences with a biosynthesised cellulose wound dressing, Suprasorb® X, in a clinical evaluation study will be presented.

Material and Methods

The study was conducted on 17 patients (chronic leg ulcer: 12, diabetic foot ulcer: 3, other: 2; wound area 2,8-10 cm², wound age 2 months – 7 years, moderate to medium exudation, period of observation about 4 weeks). The treatment consists of moist wound management: Suprasorb® X and a secondary dressing selected dependent on the level of exudation (film-, foam-, high absorbent dressing).

Patient 1

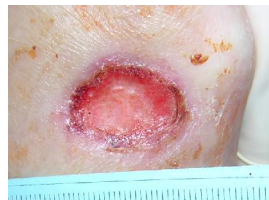Male, 66 years, Mixed lower leg ulcer, medium exudation



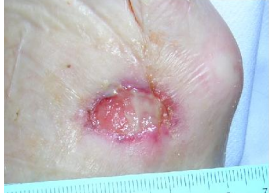From the beginning of the therapy with Suprasorb® X directly epithelisation and continuously woundclosing

Patient 2

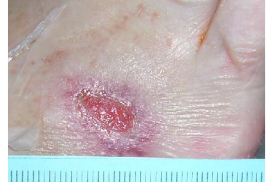Female, 77 years, Diabetic foot ulcer, moderate exudation



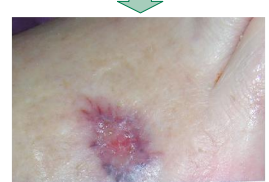day 1



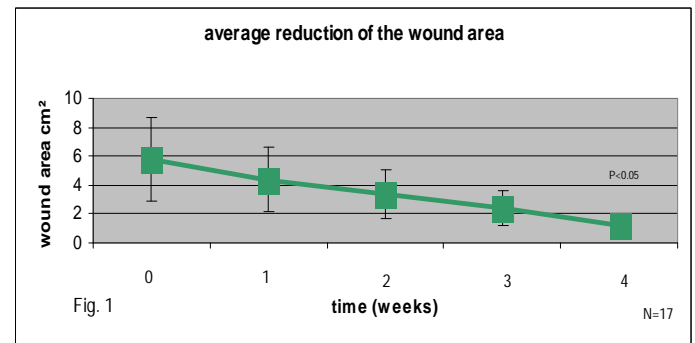
day 3



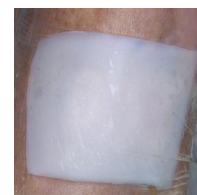day 14



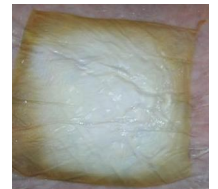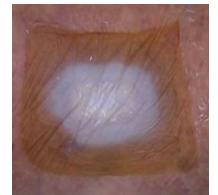
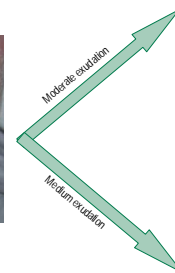
day 20: wound closed



Structural change of Suprasorb® X at different exudation stages



Suprasorb X after application



Results:

The results of the study demonstrate the following after 4 weeks: The wound dressings stayed on the wounds up to 6 days depending on the wound situation (averaged 3,82 days, +/- 2,8). Significant reduction of wound area (from 5,8 cm² to 1,2 cm² averaged, Fig. 1, $p < 0.05$) could also be observed. Efficient wound bed cleansing, fundamental growth of granulation tissue and considerably growth of epithelial tissue have also been observed (comparable with first experiences in the USA¹). Easy handling is a positiv effect for the user, a noticeable pain reduction is one of the benefits for the patient.

Conclusion

These 17 cases show an excellent clinical efficacy of the hydrobalanced wound dressing, Suprasorb® X, promoting the healing process in all wound healing stages and phases with moderate to medium exudation. Suprasorb® X is a product with a broad use and can reduce the number of products needed in daily use.

Reference:

1: Alvarez O.M.; Patel M.; Booker J.; Markowitz L. Effectiveness of a Biocellulose Wound Dressing for the treatment of Chronic Venous Leg Ulcers, Results of a Single Center Randomized Study Involving 24 Patients; Wounds (2004) 16 (7): 224-233

Annual Congress 2006 of the ETRS 13.09.-16.09.2006, Pisa