



First Report of Intraluminal Endoscopic Negative Pressure Therapy (ENPT) for Anastomotic Prophylaxis in a Case of Tubular Resection of Cervical Esophagus

Gunnar Loske*, Tobias Schorsch and Christian Theodor Müller

Department for General, Abdominal, Thoracic and Vascular Surgery, Katholisches Marienkrankenhaus Hamburg gGmbH, Hamburg, Germany

Abstract

Introduction: Endoscopic Negative Pressure Therapy (ENPT) presents a novel treatment option for leaks in the upper gastrointestinal tract. We report a first use of intraluminal ENPT for intraoperative anastomotic prophylaxis in a case of high cervical tubular esophageal resection.

Material and Method of Intraluminal ENPT: For intraluminal ENPT open-pore drainage is constructed by suturing open-pore polyurethane foam at the tip of a drainage tube. Then the drainage is placed in the esophageal lumen by endoscopic means. Negative pressure is applied with an electronic vacuum device. Esophageal lumen is occluded and drained by suction simultaneously.

Case Report: A 46 year old woman underwent tubular resection of the upper esophagus because of a retroesophageal schwannoma. Cervical end-to-end esophago-esophagostomy anastomosis was hand sewn just below the upper esophageal sphincter. Then open-pore polyurethane foam drainage was placed intraluminal covering the whole anastomotic region and vacuum was applied.

Results: Prophylactic ENPT ended after three days. Perfusion was excellent, no edema, ulceration or local inflammation were seen. Because of temporary left sided vocal cord paralysis artificial ventilation went on for one week postoperative. Endoscopy confirmed normal healing without stenosis in long term follow up.

Conclusion: This first report is a single observation of the use of ENPT for intraoperative anastomotic prophylaxis. We suppose, prophylactic intraluminal ENPT might reduce the incidence of anastomotic leaks. Further studies are needed.

Introduction

Anastomotic leakage in the esophagus is a severe complication. Recently Endoscopic Negative Pressure Therapy (ENPT) (synonym Endoscopic Vacuum Therapy (EVT)) presents novel treatment option for leaks in the upper gastrointestinal tract [1,2]. Herewith we report a first use of intraluminal ENPT in a primary prophylactic manner in a case of high cervical esophageal resection.

Material and Methods

Method of intraluminal ENPT of the esophagus has been inaugurated by our working group [3]. An open-pore drainage is constructed by suturing an open-pore polyurethane foam at the tip of a drainage tube. Open pore drainage consisting of a gastric tube and open-pore polyurethane foam (V.A.C.® GranuFoam™, Kinetic Concepts, Inc., San Antonio, USA; Endo-SPONGE™, B. Braun Melsungen AG, Melsungen, Germany; Suprasorb® CNP Wundschaum, Lohmann & Rauscher GmbH&Co. KG, Neuwied, Germany). The distal end of the foam drainage is grasped with forceps or a tripod grasper. For intraluminal therapy we prefer to use long foams with a length up to 10 cm. First the drainage is inserted by endoscopic means into the esophageal lumen with the foam part distal of the anastomotic region. Then the grasper is released. By pulling the tube the open-pore foam is placed onto the anastomotic region. The best position is, when the anastomosis is placed in the middle part of the foam, thus covering the anastomosis completely. Then the drainage tube is led out nasally and negative pressure is applied with an electronic vacuum device (KCI V.A.C. Freedom®, KCI USA Inc., San Antonio, Texas, USA, setting: -125 mmHg, continuous, intensity 10). The esophageal lumen is collapsing surround the vacuum drainage and the esophageal epithelium is sucked to the pores of the foam. Principle of ENPT is closure and drainage, simultaneously.

OPEN ACCESS

*Correspondence:

Gunnar Loske, Department for General, Abdominal, Thoracic and Vascular Surgery, Katholisches Marienkrankenhaus Hamburg gGmbH, Alfredstrasse 922087 Hamburg, Germany, Tel: 49 (0)40 2546 1402; Fax: 49 (0)40 2546 1400; E-mail: loske.chir@marienkrankenhaus.org

Received Date: 14 Feb 2017

Accepted Date: 29 May 2017

Published Date: 12 Jun 2017

Citation:

Loske G, Schorsch T, Mueller CT. First Report of Intraluminal Endoscopic Negative Pressure Therapy (ENPT) for Anastomotic Prophylaxis in a Case of Tubular Resection of Cervical Esophagus. Clin Surg. 2017; 2: 1500.

Copyright © 2017 Loske Gunnar. This is an open access article distributed under the Creative Commons Attribution License, which permits unrestricted use, distribution, and reproduction in any medium, provided the original work is properly cited.

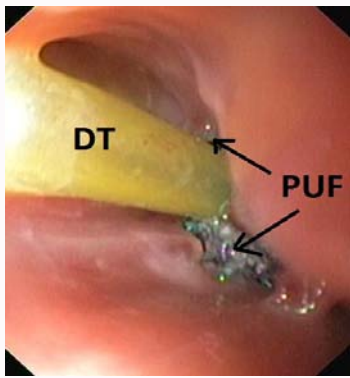


Figure 1: Intraluminal open-pore drainage in situ, drainagetube (DT), open-pore polyurethane foam (PUF).

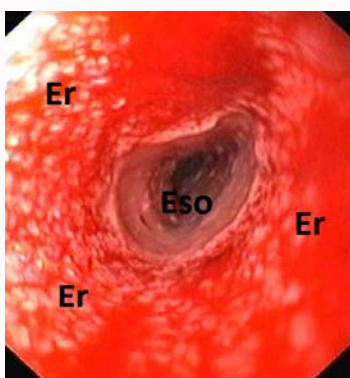


Figure 2: Anastomotic region after extraction of the open-pore Drainage, pimpled erosion pattern (Er) as a sign of effective therapy, healthy uncompromised esophageal epithelium distal of drainage contact.

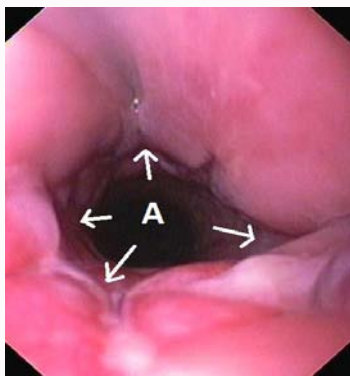


Figure 3: Anastomosis (A) 6 days postoperatively, 3 days after end of prophylaxis, erosion disappeared completely.

Case Presentation

A 46 year old woman underwent high tubular resection of the upper esophagus because of a retro-esophageal schwannoma. Cervical end-to-end esophago-esophagostomy anastomosis was hand sewn just below the upper esophageal sphincter. After finishing the anastomosis open-pore polyurethane foam drainage (EndoSPONGE[®] B. Braun Melsungen AG, Melsungen, Germany) was placed intraluminal covering the whole anastomotic region (Figure 1). Application of negative pressure with electronic vacuum device resulted in collapse of the esophageal lumen with intraluminal drainage. Intraoperatively placement procedure and correct function

of ENPT was monitored from outside and from inside by endoscopy.

Three days post-operative open-pore drainage was removed by pulling the tube. Epithelium of the foam covered region showed typical erosion pattern of the suction effect (Figure 2). Anastomosis was hidden within the circular patterned epithelium. Perfusion was excellent, no edema, ulceration or local inflammation were seen. Therefore ENPT for prophylaxis was ended and a gastric feeding tube inserted for enteral nutrition. Because of temporary left sided vocal cord paralyse artificial ventilation went on for one week postoperative. On day 4 /6 (Figure 3) and 10 postoperative endoscopy confirmed normal healing without stenosis (Figure 4), local inflammation or leakage. The erosion patterns of suction disappeared within 24 h. Normal oral feeding started at day 8 post-operative. 50 days after prophylactic vacuum therapy patient complained dysphasic symptoms caused by intraluminal non-resorted suture material (Figure 5). After extraction patient was free of dysphasic complaints immediately, no stenosis occurred in long-term follow up of more than 20 month. Course of therapy is shown in supplement video.

Discussion

Until now in esophagus endoscopic negative pressure therapy has been used in therapeutic manner. More than 230 patients have been treated with various defects of the esophagus with a success of 90% over all [2]. Recently, Neumann et al. [4] have demonstrated the successful early use in a series of anastomotic ischemia. In this case report we demonstrate the use of intraluminal ENPT for primary prophylaxis in a very high esophageal resection.

Placing procedure of the foam drainage onto the anastomotic region was monitored from outside and inside with endoscopy while operation. Along the treatment period of the first three postoperative days negative pressure resulted in collapse of the esophageal lumen. The anastomotic region was covered closely with the foam by suction. The permanent negative pressure drainage decreased bacterial contamination, secretion and local edema. Wound edges were stucked together additional to the anastomotic suturing and perfusion was

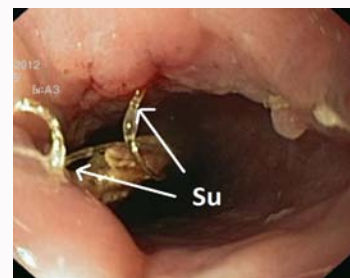

Figure 4: Intraluminal non-resorted suture material (Su), 50 days post-operative.

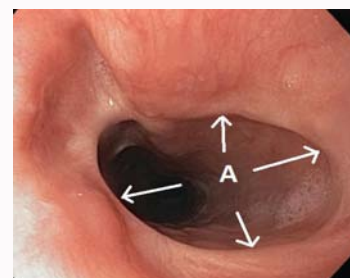


Figure 5: Anastomosis (A) 20 month post op, only a tiny scare remained.

promoted.

Intraluminal placing of the foam- drainage with a pull maneuver in the esophagus from distal to proximal is an easy endoscopic procedure. But as we know from several other treatments, insertion of long foam- drainage along the upper esophageal can be difficult. Therefore we recommend the use of an overtube to pass the pharynx and upper esophageal sphincter.

We suppose a treatment period of 3 days is a short interval for prophylaxis. ENPT was ended because of the excellent endoscopic image of the anastomotic region. The foam had come into close contact to the esophageal epithelium. Typical erosion pattern, caused by suction, covered the anastomotic region completely. Perfusion was excellent without any inflammatory signs. These findings we know from ENPT of iatrogenic perforations, here we treated for 5 days median only [5] with a success of 100%.

Negative pressure of -125 mmHg is our standard negative pressure we use in endoscopic vacuum therapy of the upper gastrointestinal tract. Since we have started ENPT in the esophagus in (2006) we hold on to use the first electronic device system we have been successful with. Current vacuum devices generate negative pressure adapted to specific benefits for superficial wounds. We assume these modern devices may be not suitable for ENPT in the esophagus.

Conclusion

Our report is a single observation of the use of ENPT for intraoperative anastomotic prophylaxis. Together with the experience in the treatment of iatrogenic perforations and esophageal anastomosis at risk, we assume this prophylactic use might reduce the incidence of anastomotic leaks. Further studies are needed to prove the benefit of prophylactic ENPT in patients with esophageal resection.

Supplement Video

Video shows the endoscopic findings in the course of anastomotic prophylaxis in a case of tubular resection of cervical esophagus.

Conflict of Interest

Gunnar Loske is consultant of Lohmann & Rauscher GmbH & Co.KG. Tobias Schorsch and Christian Theodor Müller declare no conflict of interest.

Acknowledgment

We like to thank the nursing staff of the interdisciplinary endoscopic unit of Marienkrankenhaus Hamburg for their excellent technical assistance. And we like to thank the team of the interdisciplinary units for their support.

References

1. Mennigen R, Senninger N, Laukoetter MG. Novel treatment options for perforations of the upper gastrointestinal tract: Endoscopic vacuum therapy and over-the-scope clips. *World J Gastroenterol.* 2014;20(24):7767-76.
2. Kuehn F, Loske G, Schiffmann L, Gock M, Klar E. Endoscopic vacuum therapy for various defects of the upper gastrointestinal tract. *Surg Endosc.* 2017.
3. Loske G, Schorsch T, Müller C. Intraluminal and intracavitary vacuum therapy for esophageal leakage: a new endoscopic minimally invasive approach. *Endoscopy.* 2011;43(6):540-4.
4. Neumann PA, Mennigen R, Palmes D, Senninger N, Vowinkel T, Laukoetter MG. Pre-emptive endoscopic vacuum therapy for treatment of anastomotic ischemia after esophageal resections. *Endoscopy.* 2017;49(5):498-503.
5. Loske G, Schorsch T, Dahm C, Martens E, Müller C. Iatrogenic perforation of esophagus successfully treated with Endoscopic Vacuum Therapy (EVT). *EndoscInt Open.* 2015;3(6):E547-51.